

INDUCE Oi-9™ CASE STUDY

Horizontal and Vertical Anterior Maxillary Deficiency Treated with Induce Oi-9™ FiberMatrix Bioimplant

Clinician: Dr. Charles Orth, DDS/PA Board-Certified Periodontist and Implant Specialist
Assistant Clinical Professor, Baylor College of Dentistry Director, Excel Study Club

BACKGROUND

A 28-year-old Caucasian male with a history of long-term drug abuse and no other significant medical conditions presented for dental treatment. The patient underwent extraction of the remaining maxillary anterior teeth and lower molars. Additionally, dental caries were restored on the premolars and incisors (see Image i).

The treatment plan included the placement of six dental implants and restoration with a maxillary fixed hybrid prosthesis (see Image ii). Unfortunately, during the healing phase, the patient experienced bone loss around the implants on the upper left side.

The treatment plan was revised to a full maxillary overdenture supported by locator attachments. However, due to significant bone loss and insufficient implant support, the implants had to be removed. After a four-month healing period, a substantial segment of bone remained deficient (see Image iii).

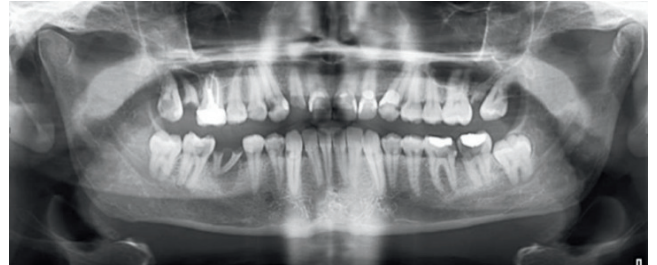


Image i

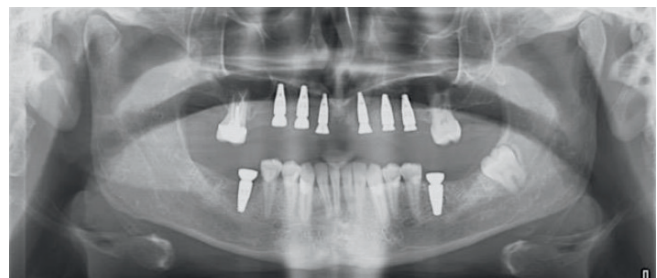


Image ii

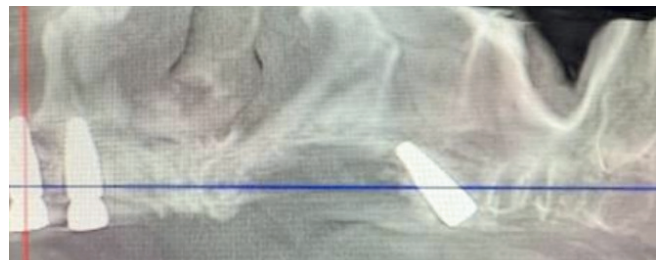


Image iii



SURGICAL PLAN

Diagnosis: Horizontal and vertical alveolar ridge deficiency in the anterior maxilla

Grafting Material Used: Induce Oi-9™ FiberMatrix Bioimplant (2.5 cc)

Membrane Used: Perforated PTFE Titanium "growth factor membrane"

Surgical Plan:

- Removal of failing implants
- Reconstruction of ridge deficiency using Induce Oi-9
- Application of titanium reinforced "growth factor" membrane
- Placement of three new implants six months post-augmentation

TREATMENT PROCEDURE

Pre-operative Assessment:

The patient presented with horizontal (see Image iv) and vertical (see Image v) alveolar ridge deficiencies in the left anterior maxilla. Preoperative 3D imaging revealed significant loss in both vertical height and horizontal width (see Image vi). Based on these findings, a decision was made to augment the deficient anterior maxilla using 2.5 cc of Induce Oi-9 FiberMatrix bioimplant.

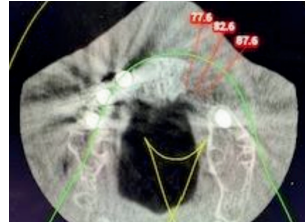


Image iv

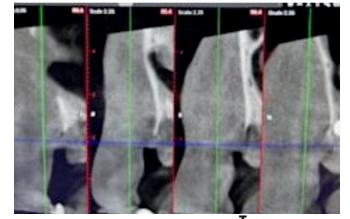


Image v

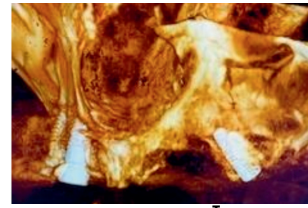


Image vi

Clinical Images:

The treatment plan was revised to include bone augmentation to reconstruct the left maxillary alveolar ridge and replace the failed implants with three new fixtures (see Images vii and viii). Induce Oi-9 FiberMatrix grafting material was selected for the augmentation, along with ridge scaffolding using a perforated PTFE titanium-reinforced "growth factor membrane" (see Images ix and x).

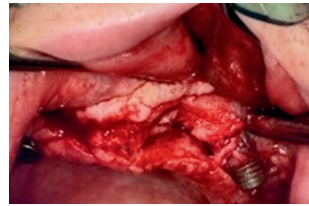


Image vii

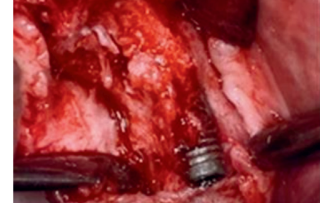


Image viii

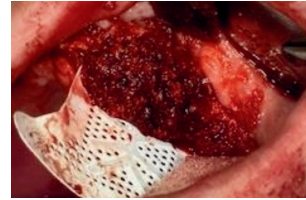


Image ix

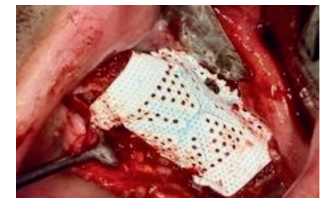


Image x

Images at 6 months post grafting:

Excellent reconstruction of both vertical height (see Image xi) and horizontal width (see Image xii) was achieved following grafting with Induce Oi-9 FiberMatrix. Despite the compromised healing environment, substantial new bone regeneration was observed in both cross-sectional (see Image xiii) and 3D imaging (see Image xiv).

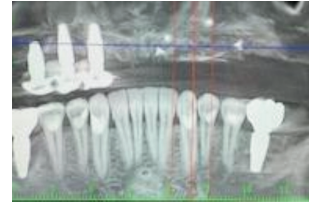


Image xi

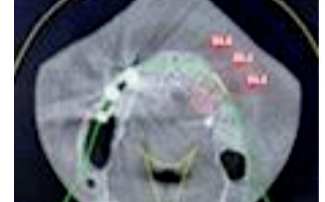

Image xii

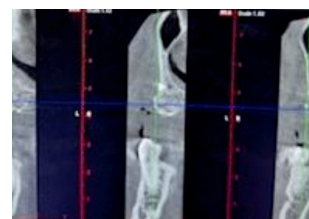


Image xiii

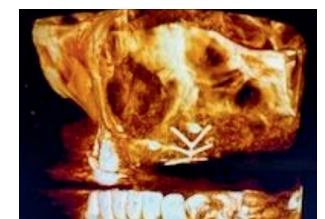


Image xiv

RESULTS & CONCLUSION

Postoperative assessments demonstrated:

- Successful regeneration of both horizontal width and vertical alveolar ridge height.
- Effective integration of the Induce Oi-9 FiberMatrix graft, even in compromised tissue conditions.
- New bone formation confirmed by cross-sectional and 3D imaging.

This case highlights the capability of Induce Oi-9 FiberMatrix to facilitate bone regeneration in a complex maxillary alveolar defect.

Induce Oi-9™ and Regeneration Naturally™ are trademarks of Red Rock Regeneration, Inc. NMP® is a registered trademark of Red Rock Regeneration, Inc.



Induce Biologics USA Inc. | 15 Cushing, Irvine, CA 92618
888-864-4906 | www.InduceBiologics.com
MKT-097 Rev 01

